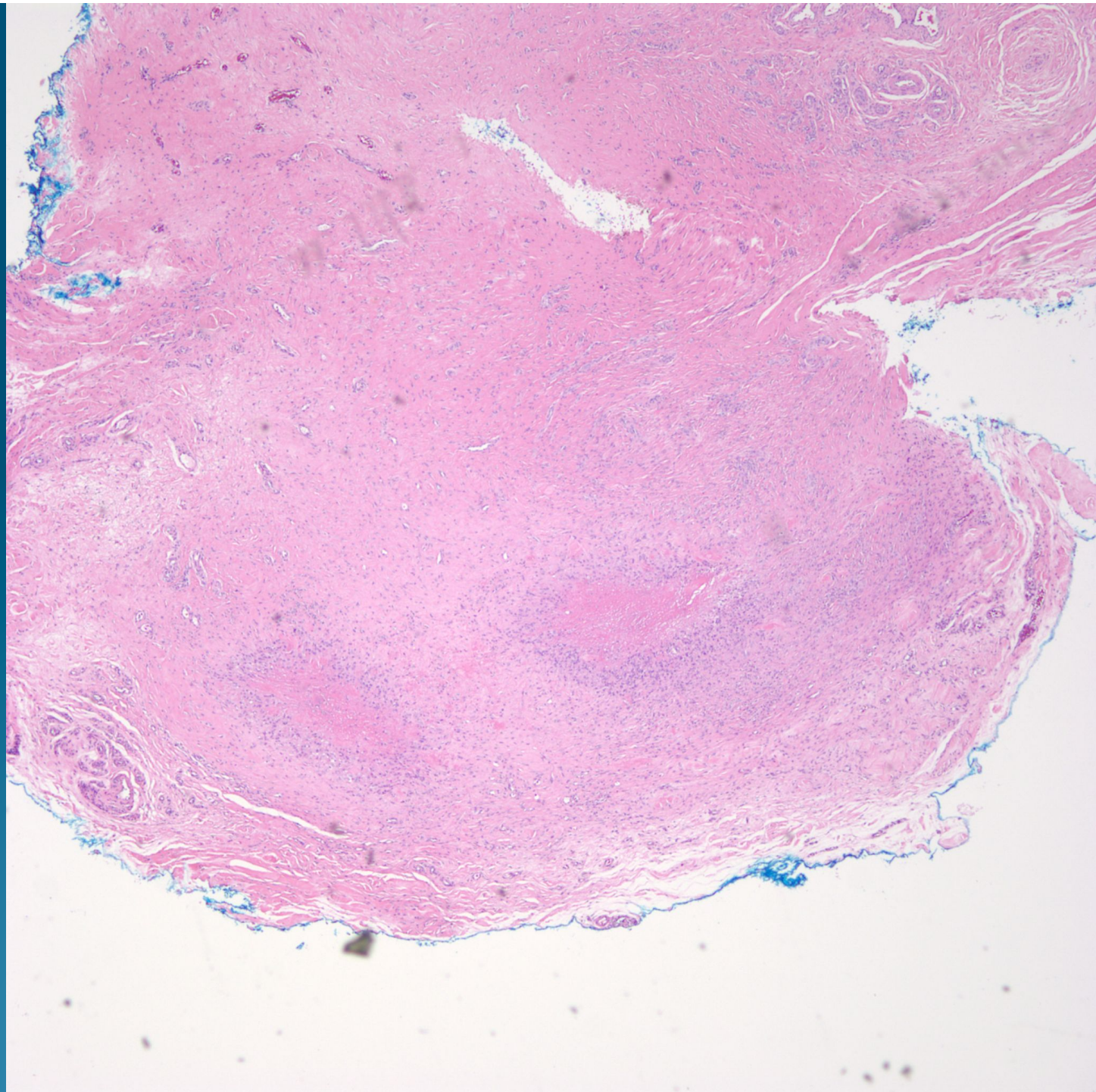
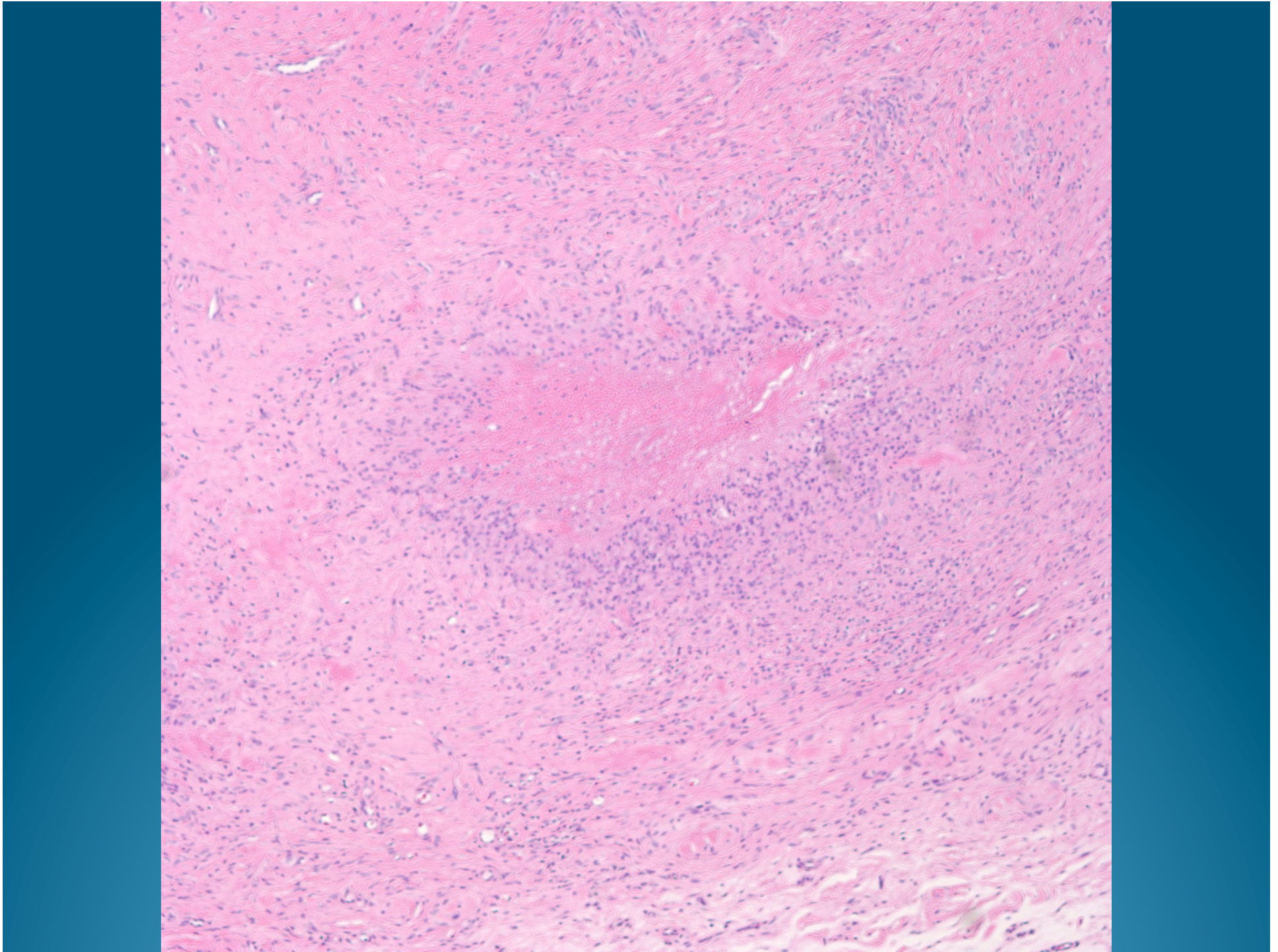
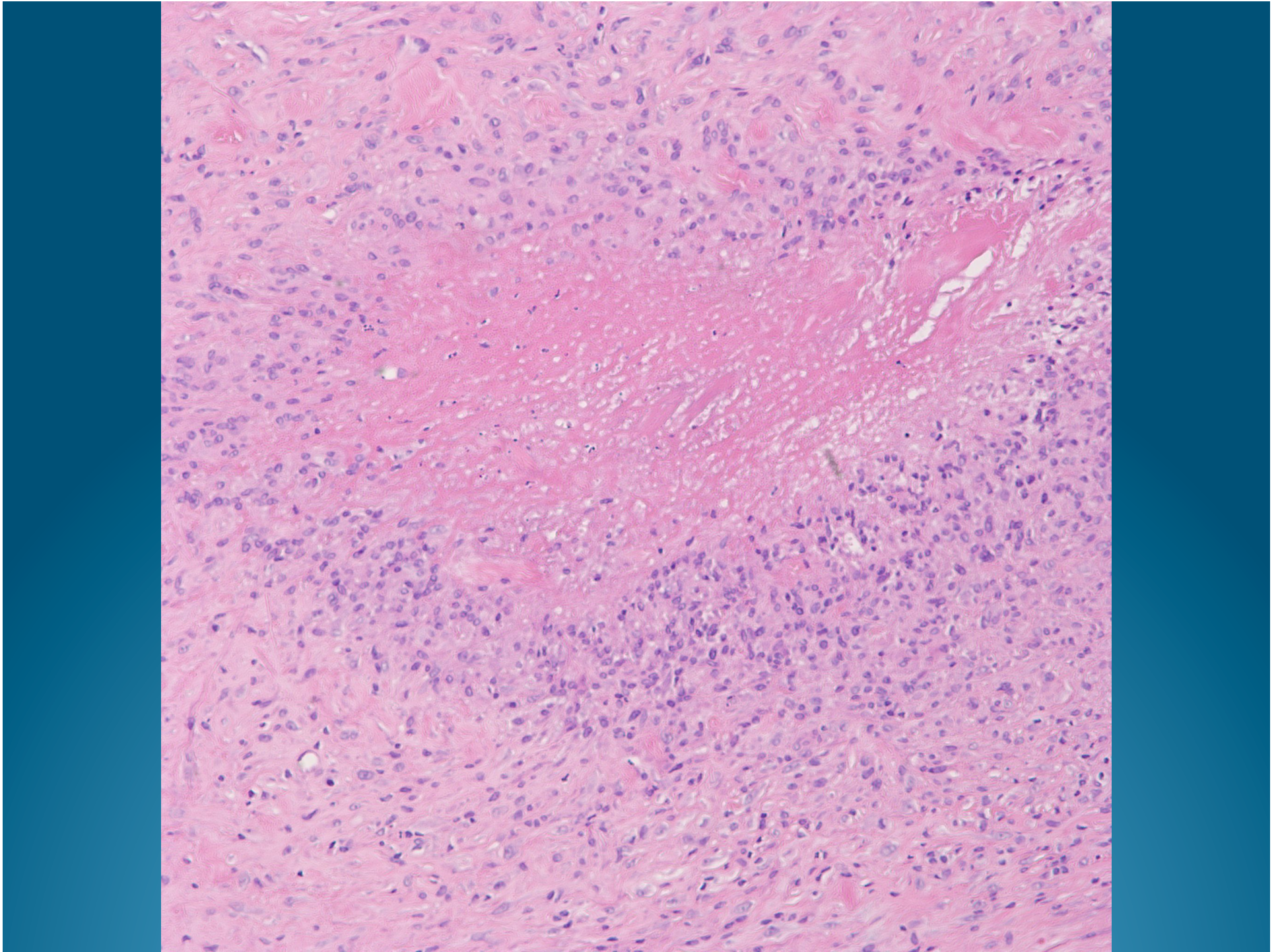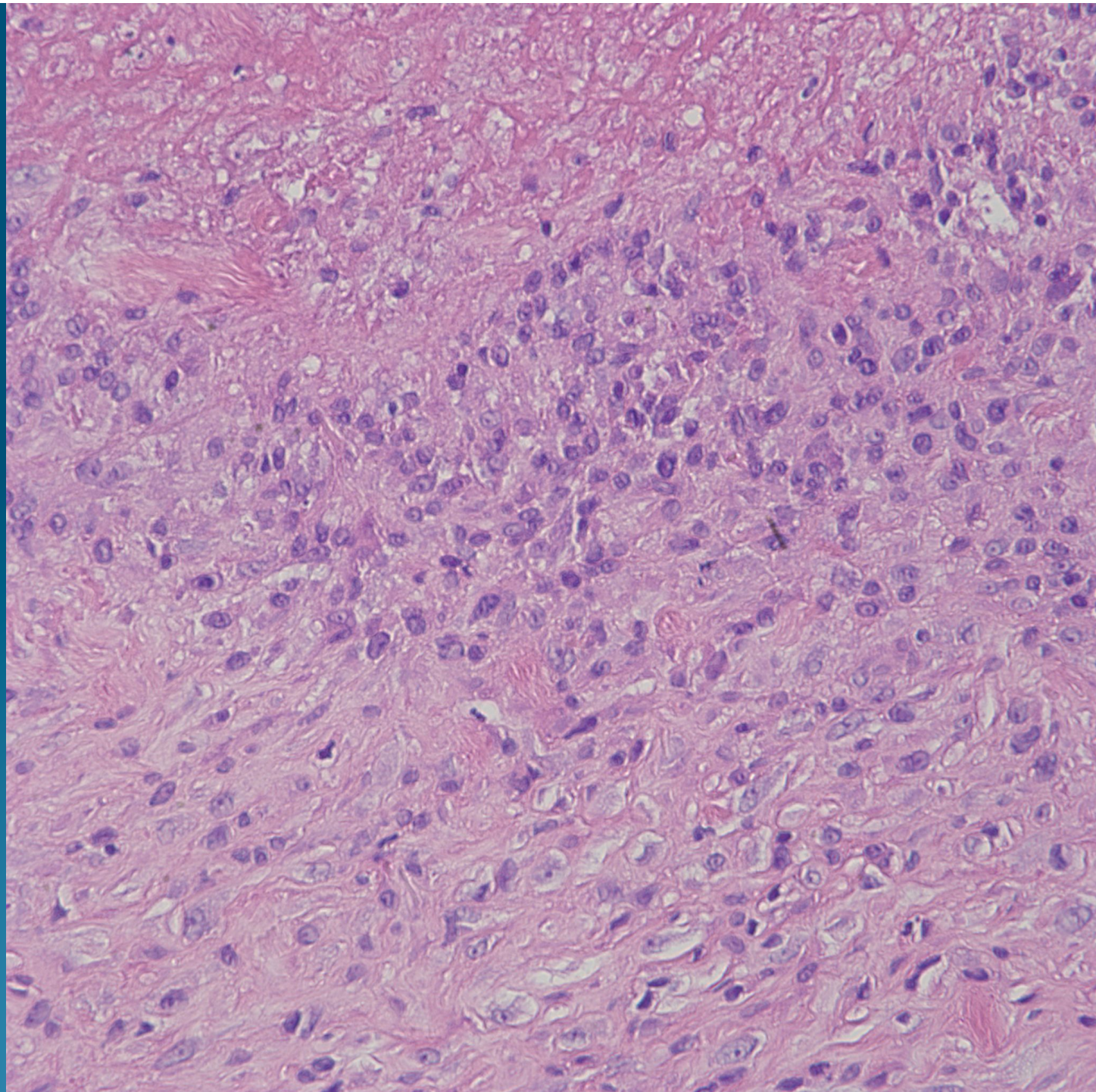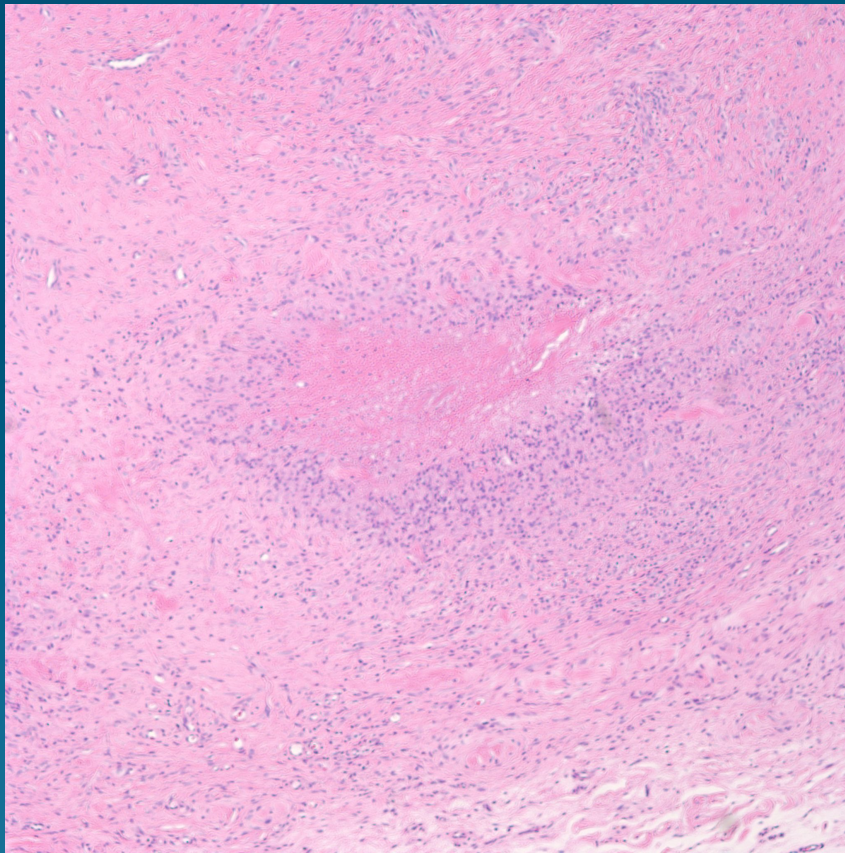
# What is the best diagnosis?

- A. Rheumatoid nodule
- B. Necrobiosis lipoidica
- C. Churg-Strauss granuloma
- D. Sarcoidosis
- E. Necrobiotic xanthogranuloma

# Rheumatoid Nodule



# Pearls



- Palisading necrobiotic granuloma
- Usually deep reticular dermis
- Lined by epithelioid histiocytes and plasma cells
- Minimal mucinosis
- Always rule out infection and foreign body granuloma